

Epilepsy – A New Public Health Concern?

Dr. Joachim-F. Grätz, Oberhausen i. Obb., Germany

Translated by Uwe Heyeres (Germany) and Marion Heyeres (Australia)

Proofreaders: Matthew Rawlins (USA), Claire Jones (Australia) and N. N. (Great Britain)

Until a few years ago I had no clear understanding of epilepsy and its symptoms. During my homeopathic training I assumed it highly unlikely to be presented with a disease such as epilepsy as it was rather uncommon. Up to that point I didn't know anybody suffering from epileptic fits, nor did I witness any fits myself. However, after 20 years of practicing 'Chronic Homeopathy', epilepsy has become a central theme in my practice and I am convinced that it is more widespread than people tend to believe. The drastic increase of new Epilepsy Centres state-wide that specialise in drug therapy for children and adults and the administering of anti-epileptic medication supports my assumption. This trend is also observed in other 'modern' diseases and seemingly unstoppable. To put it in a nutshell – more and more people suffer from epilepsy, just as with other serious diseases of modern times! Epilepsy has become a public health concern¹ – the question is WHY?

¹ According to Harris L. Coulter, epilepsy was very uncommon in infants and toddlers in the USA until 1950. "The entire medical literature between 1841(!) and 1948 showed only 62 cases (Coulter, H. L., "DPT – A Shot in the Dark"). Between 1950 and 1963 there were 1,453 cases reported and in 1964 there were already more than 3,000 known cases in North America alone! This has become worse today and not just in the USA! Even here in Germany we have thousands who are affected by it. The tendency is progressively increasing in numbers – worldwide!! The same applies to India, Mongolia and anywhere else in the world! This is at least according to my professional homeopathic experience.

Traditional Viewpoint

According to the medical dictionaries 'Pschyrembel' and 'Roche Lexikon Medizin', epilepsy is the so-called 'falling sickness'. The manifestation of the disease is characterised by the repeated occurrence of fits, accompanied by general (Grand mal) or limited (non-generalised) seizures (partial or focal epilepsy) or with seizures that are short lived (Petit mal). The seizures are generally characterised by unconsciousness, and tonic and/or clonic¹ twitching of the extremities. It is not unusual to be announced by a so-called 'Aura'².

¹ Tonic seizures: seizures of great intensity and duration

Clonic seizures: fast, successive short-lived twitches of counteracting muscles

² Aura: short lived precursing symptoms, appearing directly before general seizures; a general short name for the epileptic Aura, which in turn may also be a singular symptom of the fit itself.

Conventional Therapy

Traditional therapy for epilepsy “is meant to keep seizures under control“ and to suppress the symptoms without any focus on healing! In rare cases, should magnetic resonance imaging or computer tomography prove the ‘comprehensible brain illness’, the cause is surgically removed and, followed by long-term therapy administering antiepileptic medication. At times, multiple medications are administered simultaneously. Furthermore in many cases an ACTH¹ injection therapy is tried; for a couple of years also a ketogenic diet² with children.

Epilepsy is seemingly viewed as something evil and in need of eradication. With every seizure, apparently thousands of brain and nerve cells are being damaged and partially even die.. For this reason all seizures are to be suppressed with medication. However, so far nobody has really seen that indeed large quantities (or even only a single one) of brain and nerve cells are dying off. How should we? Modern technology, e.g. magnetic resonance imaging (MRI) is far too vague as it shows only dark and light shades. To achieve a definitive result, one would need to surgically open the skull to count and compare the billions of microscopically small cells. This is impossible and can therefore only be an interpretation!

Traditional therapy chooses strong chemical medications that produce a vast array of side effects. This can be almost fatal for small children who are still developing as it is not rare that the biologically normal development becomes stunted. Consequentially, we speak about developmental disturbances and retardation and don’t realise these are not the result of epilepsy itself but of the conventional therapy’s massive side effects. That is of course unless they pre-existed for other reasons.

Natural Law of Disease

In order to understand epilepsy regarding its biological course, let us examine some biological laws of nature regarding health and disease.

When diseased, the organism switches from the healthy, vegetative innervation – the natural rhythm and constant change of actions between sympathetic and parasympathetic (vagotonic) part of the nervous system – to ongoing sympathicotonia (see Figure 1). From a neurological standpoint, the organism experiences long-term stress without vagotonic respite. This vegetative long-term stress phase will be at a later stage after its resolution (as space is limited, I am not able to go into detail about this here) is replaced by the second phase of the disease, the ongoing vagotonia. This is the repair stage or also the healing phase. Traditionally, this latter phase is viewed as the actual illness. During this ‘warm’ phase, with all its typical symptoms such as fever, tiredness, lethargy, and the appearance of microbes (e. g. Streptococcus,..) the

¹ ACTH: *adrenocorticotrophic hormone* (corticotropin), which is produced and secreted by the anterior pituitary gland.

² Ketogenic diet: a high-fat, adequate-protein, low-carbohydrate diet that is used primarily to treat refractory (difficult-to-control) epilepsy in children; which means – biologically viewed – a thoroughgoing malnutrition.

Epilepsy – A New Public Health Concern?

TISANI VERLAG

tissue that was affected during the first phase will be repaired step by step. Tissue that proliferated will be removed and tissue that “melted down” will now be rebuilt by mucous secretion. This process is often accompanied by fever and is commonly viewed as an infection or inflammation. These evolutionary facts have been happening this way for millions of years and are determined by the respective germ layer classification of each individual tissue or organ, as well as the respective control relays in the brain.

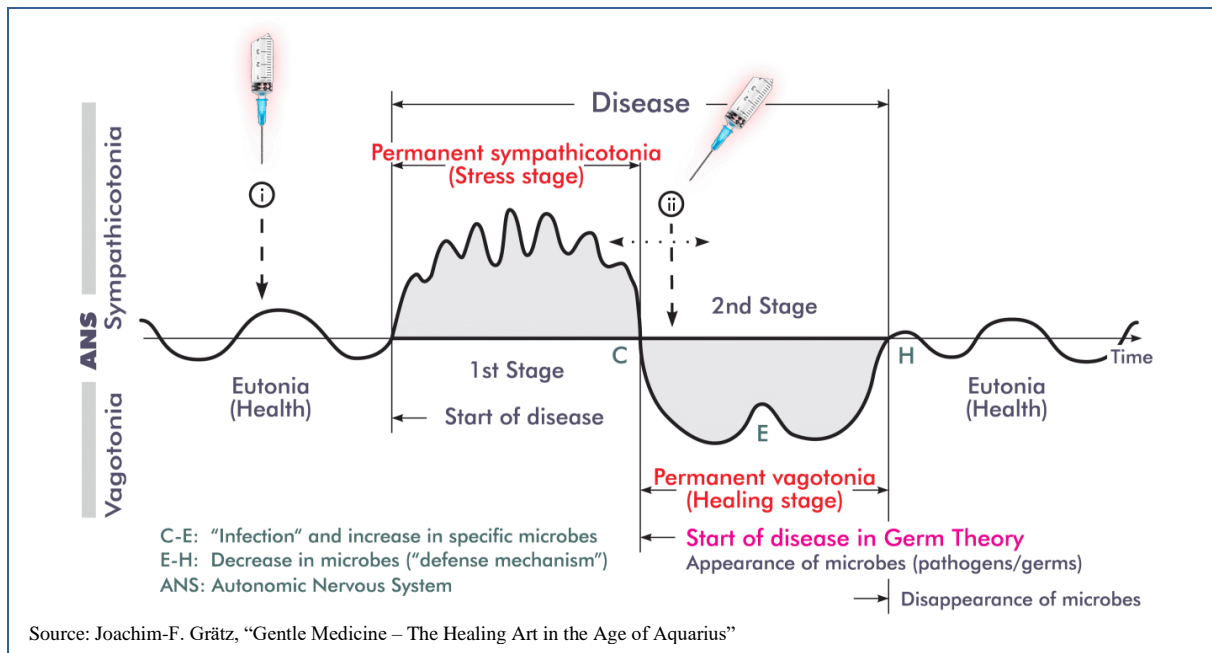


Fig. 1: The two phases of diseases with permanent sympathicotonia and permanent vagotonia

Epilepsy Viewed Cerebral Organically

The cerebral organic view is that during the so-called stress phase of the disease it comes to a *regional demyelination of the brain*. This particular area is then filled with an edema that promotes healing. Depending on the length of the pre-cursing sympathicotonia, this swollen area appears on the computer tomography scan (CT) as a ‘space demanding process’. The reason for this cerebral organic, biologically completely normal process is the *creation of new glia tissue (connective tissue of the brain)* in order to re-isolate the short-circuited nerves. During the peak of the vagotonic healing phase, identical with the maximal markedness of the brain edema, there will be a time when the organism attempts to free itself from parts of the brain edema to slowly return to normality (Figure 2: Point E). – At exactly this turning point, the maximal space demanding of the brain edema equals the epileptic seizure!

Therefore, epilepsy itself belongs to the healing phase of a disease. It is the cerebral organic part of the peak of nature’s emergency and specialised response to put things back in order. In reality, epilepsy is no separate disease but only a consequence of extreme pressure in the brain that is caused by a highly congested edema. That in turn affects the motoric centre in the cerebral cortex, the *Precentral gyrus*. This edema occurs exclusively during the vagotonic heal-

Epilepsy – A New Public Health Concern?

TISANI VERLAG

ing phase and promotes repair activities in the brain. Therefore, strictly speaking, this is no malfunction of the brain in the original sense that needs to be fought and is definitely no massive brain cells die-off!

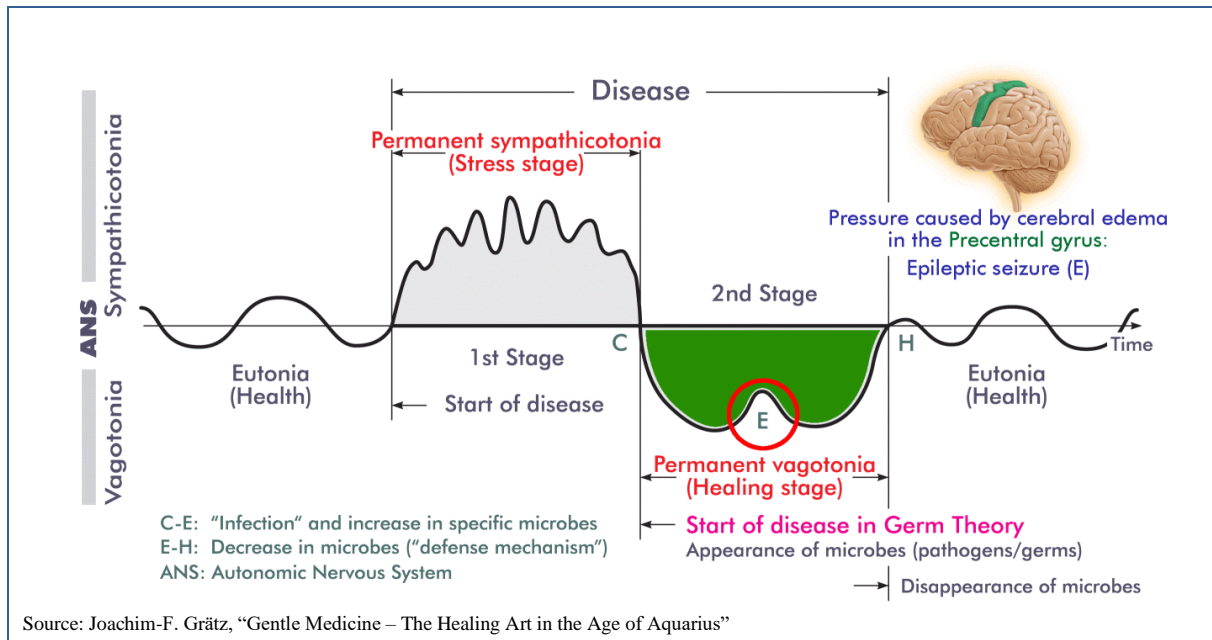


Fig.2: Epilepsy in the focus of the two phases of diseases

Main Causes of Epilepsy in Modern Times

The *main causes of epilepsy* are by far *immunisations*. Because of them, on the basis of the initiated long-term sympathicotonic condition, it can come to a *disruption of the myelinisation process during infant age* (so-called *post-vaccinal encephalopathy*, a diffuse inflammation of the brain with demyelisation post vaccination). This applies particularly to children under the age of three as brain development is largely completed only towards the end of the third year of life. Immunisations can also lead to a *demyelisation of single parts of the brain at a later stage in life*. This is at least my experience as a practicing Homeopath. Furthermore, in rare cases *suppressive actions through conventional material medications*, e.g. antibiotics or cortisone may also trigger epileptic seizures. Epileptic seizures can also occur after *severe skull-brain traumas* as well as *post-surgery scarring of the brain*. Even *persistent fear and panic attacks* should be mentioned as well as *very difficult and/ or premature births* (based on motoric and/or fright-fear conflicts that have their cerebral organic localisation among others in the sensorimotor cortex)¹. In these cases any fits pass far quicker and occur less frequently when speaking of chronic epilepsy.

¹ For more information please refer to my publication "Klassische Homöopathie für die junge Familie" (Classical Homeopathy for the young family), 2nd edition 2001/2003, 2 vol., in particular the chapter "Entwicklungsgestörte und behinderte Kinder" ("Developmentally disturbed and handicapped children")

Epilepsy – A New Public Health Concern?

TISANI VERLAG

Initial Appearance of Epilepsy – Example 1

Paul, 4 years old

"Paul developed normally throughout his first year of life; in the first few months he was even above average. He was noticeably happy, enthusiastic without being restless, well balanced and open towards strangers. He was never scared of strangers. When he was 14 days old, I greeted him with 'Hello, little Baby!' Paul replied with a clear 'Hey'. At four months I visited two friends whom I met in the hospital after delivery. We put our three kids next to each other on the floor. Paul was lying for the first time next to a child of the same age. Soon he turned his head happily towards the other baby and grabbed his tummy. At 15 months he achieved the lower percentile in a 'development test' (Münchner Brückentest). He handed over his pacifier purposefully after being asked. He was able to stand unaided. He was open to other children and shared his toys. Paul was able to put a round block into a box with variously shaped openings. At 18 months he pointed purposefully to objects, walked 8 steps unaided and said once a two letter sentence. He knew 12 words in baby language. He loved particularly playing with balls and if another child wanted to join, he rolled the ball towards them."

So far this is the beginning of a written report from a mother about an initially normal appearing development during the first month of her 'epilepsy-ill' child. However, today – Paul is now 4 years old – his actual stage of development is equivalent to "approx. a child of 15 months"!

At the age of 4½ months, Paul had his "first grand mal seizure that lasted 15-20 minutes", which was one month after his immunisation with 6 different antigens to which he otherwise didn't noticeably react. In the hospital he received a "30-minutes long lasting lumbar puncture", which initially gave no concrete results. About one month later, *after the third immunisation with 6 different antigens (sextuple immunisation)*, out of the blue he came down with severe pneumonia and more grand mal-seizures. Despite them being instantly treated in hospital, a series of big, up to 36 minutes long lasting seizures followed. For the first time the diagnosis 'epilepsy' was "officially" noted and Paul was "medically adjusted in the Epilepsy Clinic for Children and Youth in Kehl-Kork". There, they experimented with several different anti-epileptic medications; at times Paul received three anti-convulsive medications at the same time. Over the years, the boy received 2 medications that suppressed his seizures. In order to get on top of his seizures, the dose for one of them was 3.25 times higher than normal; non-permissible for his age.

"Since then, Paul's development has been going backwards" his mother remembers. At first gradually, then progressively... "Paul lives in his own world... he has autistic characteristics."

Epileptic Seizure – Part of the Healing Phase

This is a fundamentally different view of epilepsy. The aura of mystery is vanishing into nothing once one understands the biological laws. *Epilepsy is a very small piece of the puzzle of nature's overarching repair program after severe brain-organic damage. It is reversible provided there is no continuous manipulation with material medication.*

Despite this new view, one should not underestimate or trivialise epilepsy. Even on a homeopathic anti-miasmatic therapy, epilepsy is to be taken very seriously. However, no brain cells are dying and the new message is and you can recover fully as if nothing ever happened! Mind you, a prerequisite is there wasn't too much prior traditional medical manipulation, and especially no brain surgery. Furthermore, during a chronic homeopathic therapy acute illnesses are to be permitted, no matter of what nature, as they are usually an expression of vagotonic healing phases. That is of extreme importance for the chronic overall healing process and therefore also for the healing of a tendency to epilepsy. That means it is strictly forbidden to suppress acute illnesses with anti-pyretic suppositories, antibiotics or other material actions. Even to root them out right at the core through household remedies is wrong, as the body will lose its ability to react through these kinds of actions.

Conventional Therapy under Scrutiny

In summary, one can say that epilepsy is a cerebral organic phenomenon occurring during the vagotonic healing phase. It is based on an *edema*, either located in the *motoric area of the cerebral cortex* or at least large enough that it affects the area. As the healing process pro-

Initial Appearance of Epilepsy – Example 2

Lena, 3½ years old

Lena experienced her first seizures at age 10 months during a "Herpes infection". Her parents reported that Lena produced a temperature of 40.7 C but showed "no symptoms otherwise". Even the typical herpes blisters did not show. However, the little girl screamed quite often with a very shrill sound. She was very hard to comfort and she also drank very little. The diagnosis was established solely through a blood test. In the hospital, Lena received *Zovirax infusions* for 10 days and her *fever was lowered*. "Eventually, she became drowsy and unable to wake up, until all of a sudden the first big seizure happened. It was terrible! – In addition she contracted a *rota virus* that had to be *treated with antibiotics*." The girl continued to fit even though she received numerous medications. "During the past 3 years she was medically adjusted with various anti-epileptic medications."

Lena was a "preemie", she was born one month early and weighed only 1790g. Only one week after her birth she received antibiotics for two weeks "for a suspected sepsis". But still, even then there were no clear symptoms. Lena was just drowsy and did not drink very well; otherwise she was fine. One week after this treatment "slight twitching on hands and body" occurred during her sleep, which was continually observed for the following four weeks. The doctors classified them as "benign infantile seizures" and therefore viewed them as relatively harmless.

Lena was vaccinated for the first time at the age of four months: a *sextuple immunisation*. The girl reacted with a "slight fever". She received the second *sextuple immunisation* one month later and the *third stage* after another month. Lena "played quite nicely" during that time, "she put everything into her mouth", her head control was good, she moved about on her tummy, she was able to prop herself up and she could sit. "Today, she only lies about, is unable to support her head, has no coordination, doesn't speak and has up to twelve daily absence seizures. To put it in other words 'blinking out', and the list goes on!"

Therefore, also in this case we can make a *clear reference to immunisation including massive suppression*. Even the initial antibiotics that provoked the infantile seizures is part of it. In continuation, the so-called herpes infection seems to have been more likely an expression of a rather late, however very acute *post-vaccinal encephalopathy* (diffuse inflammation of the brain with demyelisation post vaccination) with irritation of the meninges. An unmistakable indication for this is the continuing, very high fever and the *Cri encephalique*, the specialist term for the inconsolably shrieking girl with the so-called 'brain-cry'. This acute irritation of the meninges was "brutally beaten into submission" with medication. As a result of the manipulation with conventional material substances and in the sense of 'suppressive action', the body's innate healing force answered with diarrhoea, e. g. the *rota virus*. This was tantamount to a last attempt to clear the organism from the harmful substances. However, even this sensible undertaking of nature was misunderstood by allopathic practitioners who interpreted it as a nasty hospital germ and found the fitting answer in the form of yet another suppressive medication; the ongoing treatment with antibiotics. Consequently, the active process to complete recovery was attacked again, maintaining increasing convulsive activities. The following years consisted of medicated suppression of these seizures with extremely harmful substances. The result is 'chronic epilepsy', due to an unfinished healing of encephalopathy post vaccination, together with extreme developmental retardation, and even the 'unlearning' of already achieved developmental milestones and eventually permanent disabilities.

gresses the pressure of the edema on the centre of the "voluntary motor skills" increases, which in turn results in increasing convulsiveness. However, conventional medicine sees that as unwelcomed and even as something fatal due to an ignorance of the biological context. Therefore, anti-epileptic medication is prescribed to get on top of this actually welcomed, interim condition. That means the modern, conventional medicine massively hinders the natural-biological function of 'flushing out' the brain edema and therefore cements the status quo, even shifting it to become chronic.

Homeopathic Treatment – Case 1

Infant with West-Syndrome (A Type of Encephalopathy with Psycho-Motoric Disability)

Ines, aged eight months has been suffering from epileptic seizures (BNS cramps¹) for the past four months. Her parents recognised the onset of the seizures after the *second multiple immunisation (DPT together with HIB)*. Since then, her parents initially reckoned Ines experienced frequently episodes of being extremely frightened. Mind you, they identified an increased tendency to being frightened already after the first immunisation, however initially did not worry about that because this was not clearly identified as cramps.

True seizures were observed later on after sleeping. Furthermore, there was jerking during falling asleep; sometimes only once a day, then again more frequently, most of the times before, after or during sleep. For the past six weeks her 'health has gone downhill rapidly'. Ines seems apathetic and follows objects with her eyes only for a very short time and eye contact is diminishing. No more laughter, no 'singing'. She does not react anymore when spoken to. Staring eyes. Her liveliness decreased. Instead she became increasingly fidgety. There was no more coordinated reaching for things. She is turning over less frequently. While driving in a hot car she gets restless, screams and cramps. These conditions appear at times in sequences, up to seven times in a row. On the other hand there are sometimes several days without any attacks. The cramps appear to be of varying nature and look like following: arms and legs stretched out, eyes staring; legs folded, arms folded, eyes staring; head nodding; shaking of whole body; hands in fists with thumbs inside fist; for the past week also twitching of mouth with snorting, screaming and laughing before or after the attack or mouth squeezed together tightly. Recently, high frequent general 'Kloni'² started following the typical picture of symptoms, lasting about two to three seconds and after that whimpering for a few seconds. In the children's hospital, she was medically adjusted with Sabril (anti-epileptic medication) and discharged with a 'good EEG' (before, it was a severe pathological EEG in accordance with Hypsarrhythmia³, which is a sign of a central cerebral dysfunction, a brain dysfunction). Already after one week, the dose of Sabril had to be doubled as the cramp attacks appeared again more frequently.

The diagnosis was 'West-Syndrome', encephalopathy in infants described first by the English doctor W.J. West, marked by the following triad: 1. Generalised small attacks (Petit mal) focal and multi focal origin (salam spasms); Hypsarrhythmia (diffuse mixed cramp potentials) during EEG (diagnostically leading); *psycho-motoric developmental disturbances*; The prognosis is overall undesirable and essentially, based on the type of underlying encephalopathy, determined by possibly big epileptic seizures in the future. That meant, in the case of little Ines explicitly: psycho-motoric disability, which means lifelong mental and motoric disabilities. She would never be able to sit, let alone stand and walk; not to mention cognitive abilities...

That's so far to the report of the actual condition of the little girl at that time. Conspicuously, this all started *after immunisation*; before, the parents confirmed by showing pictures and videos that the child was completely normal and 'as fit as a fiddle'. Unfortunately, this case is *not isolated!! Complications and vaccine damage of that kind are on the daily agenda more and more frequently!* They are literally piling up in the homeopathic practice, *in particular since the use of multiple vaccinations, but also after the latest vaccination for the Rota Virus in Austria. Without exception – at least in my practice – so far, I always found a direct correlation between epilepsy and immunisation.*

The situation today: After several years of homeopathic anti-miasmatic therapy, Ines is in perfect health; she can walk, speak and do everything children her age can do. The best present for me as a therapist was – would you believe it – that Ines started school early (!!), and she actually attends a normal school! She desperately wanted to stay together with her friends from kindergarten. By now she is in fifth grade (Grammar School) and is a very popular and excellent student; she received five A's in her last report card!!

¹ BNS-cramps: Blitz-Nick-Salam-Cramps; as epilepsy manifestation often combined with progressing mental decline, including of rapid flinching of the body with forward flinging of arms and legs (Blitzkrampf), as bending over double of torso (Propulsive-Petit-Mal), as bending of head and bringing together the arms in front of chest (Salaam-Cramp), or as nodding (Nod-Cramp)

² Kloni: shaking cramps

³ Hypsarrhythmia: a specific type of a severe pathological EEG, often at severe disabilities and BNS-cramps

⁴ focal: originating from one source

It appears the anti-epileptic medication blocks the 'flushing out' of the cerebral edema with seizures halting temporarily or only very small, unremarkable ones occurring. Therefore, there is no possibility for a genuine biological healing because the excessive edema remains in the region it currently is. With time, the organism will summon all its energy reserves in an

attempt to fight the edema, and causes a build-up of liquid in the brain. After a long seizure-free phase and despite heavy anti-epileptic medications, severe seizures will occur again suddenly, e. g. a generalized fit or being classified even as *status epilepticus*¹. Traditional medicine reacts with “that is not supposed to be” and increases the dose of the cramp-suppressing medications. Or administer much stronger, very intense medications and at times additional ones. The small patient is moved back into ongoing sympathicotonia and literally “drowns in the brain edema”. Healing good-bye! What follows is constant experimentation with the dosage of the anti-epileptic medication or several medications, with the risk of additionally strong side effects; recording of all seizures; assessing of reasonable side effects and their treatment; repetitive blood tests and other laboratory parameters and in particular the testing of the liver enzymes and much more. The medical term for these procedures is “medically adjusting” and only a few realise that these procedures stunt any biological normal development. This is basically a vicious circle. At some time you have arrived at three (or even more) simultaneously administered medications in ever increasing dosages. With time this causes serious developmental dysfunction that’s very hard to correct later. In reality, to achieve true healing the patient would have to experience the ongoing vagatonic healing phase again to complete the vicious circle perfectly. Last but not least, with the continuing seizures you may end up with being labelled “beyond treatment” which equals a medical defeat. Orthodox medical practitioners have no idea what to do next as they have tried all sorts of things and everything “in their power”. Without satisfying results they are of the opinion “you can’t do anything anymore” and will call the patient “incurable”.

Looking at the presented biological background information above, orthodox anti-convulsive therapy is anything but sensible; it’s virtually reprehensible. Natural phenomena of critical healing phases, e.g. epileptic seizures should be categorised and therapeutically acted upon in a completely different way. To be exact, therapy should be carried out the opposite way of the current ‘state-of-the-art technology’. One shouldn’t suppress the willingness to cramping (*suppressing of the healing phase*), but rather promote and support it. That brings us to the homeopathic laws as described by Hahnemann almost 200 years ago (Keyword: “*homeopathic initial aggravation*”). It’s the only way gradual recurrences, e.g. frequently caused by dreams (e. g. anxiety and panic dreams, nightmares), can be lessened and as therapy progresses eventually prevented so that positive development can be expected. This is the only way to strengthen the organism to gradually heal the enlarged brain edema and to return to normality as defined by nature.

¹ According to the German pharma drug index “*Rote Liste, 2005*” (Red List) you can find a remarkable sentence regarding the side effects of anti epileptic medications: “As with other anti epileptic medication there is a possibility of an *increase in seizure frequency including status epilepticus!*” This is due to medications; you would actually expect to achieve the opposite effect.

Homeopathic Treatment – Case 2

Adult epilepsy after Suppression with Cortisol

A young father of two children has been sent by his sister. He has suffered from occasional epileptic seizures for roughly eight years. They are generalised seizures – anywhere on the body and recently increased in frequency. In total he experienced seven Grand mals so far. The last two lasted for about two minutes. One from the prior year was so severe, he “felt it for several more weeks”-

During his civil service in a youth hostel about nine years ago, while working with paint his whole body had an allergic reaction which manifested in a total body skin rash, with many red, very itchy spots. He had to be hospitalised and was *treated with Cortisol and other suppressive medications*. The therapy went on for eight to nine months before the rash cleared up completely.

At age seven his tonsils were removed because he snored. They were neither regularly purulent nor highly inflamed. Yet, for the past seven years he has been constantly coughing and was very susceptible to colds. “Almost each month there is a new infection; I am often hoarse and have bronchitis.” That wasn’t the case during my school years (until approximately ten years ago).” In addition, he has been sweating easily and often for many years now, which was clearly visible during the consultation in my practice.

The last four seizures occurred in connection with excitement, e. g. his sister’s wedding or during the completion of his Master’s degree. “I am a nervous type”, he says about himself. He is always very nervous during exams and also sensitive to noise. Leading up to a seizure he always has a strange feeling of dizziness connected with fainting...

A typical case of *suppression!* The allergic skin rash was fought against with heavy orthodox medication for almost nine months, until there was peace at last. However, the innate healing power was forced to find an alternative vent, which resulted in the tendency to cold and the occasional fits!

About two month after commencing therapy, the patient called and reported that just after 3 weeks he felt as if another attack was coming on. He sat down for 10 minutes and waited, but nothing happened. He felt better again right after. After that, he went to bed and slept. Later, after using 3 drops, he reported a permanent feeling of dizziness, which stopped with a 4th drop. There were no specific problems being on 5 drops. “Strangely enough, I have never caught a cold, neither in a draft or when getting cold after sweating”. – The patient seemed astonished, but was happy – something that was clear for the therapist, as it was meant to be! At this stage it looked already like the time for seizures was over. The ‘almost seizure’ was rated as a ‘rewind’ and the absence of tendency to infections was also going in this direction, which was confirmed by the following years.

Homeopathic Treatment of Epilepsy

As epilepsy is viewed primarily as a chronic condition, homeopathic therapy has to be carried out first and foremost *chronic anti-miasmatic*, taking into consideration all discernible causes and correlations. Meanwhile, you won’t be able to avoid using acute homeopathic remedies that are strongly regarded by epileptic seizures. These acute remedies come in handy, especially in recurring and long lasting seizures or even in series of seizures. Basically, you can view the *acute seizure as acute exacerbation of a chronic burden* so that on the one hand you *treat therapeutically the acute situation* in order to *take the edge off the symptoms*, – e.g. with a status epilepticus – and to avoid strong orthodox medications. On the other hand – you take in account the *miasmatic background* in order to *make the tendency to cramp disappear* with time. Looking at it from a purely acute viewpoint – as usual – only the acute symptoms of the acute situation are taken in account in finding the homeopathic remedy. Whereas in the case of a chronic therapy there are also correlations to immunisation, suppressions, state of anxiety and other past illnesses. Highs and lows in the life of the patient pathological behaviours as well as their modalities are relevant. Therefore, just the same as looking at other chronic ill-

nesses, a complete life anamnesis including family anamnesis of the blood relatives is required.

The Value of EEGs during Convulsions

In conclusion, a few general words to the topic of EEG and its diagnostic value regarding epilepsy or epilepsy-similar phenomena. Taking an EEG during an epileptic seizure is actually relatively ridiculous as visible cramping actions are always to be expected during cramps solely due to the actual appearing phenomena of pressure to the brain. In other words, during phases of frequent epileptic fits, pathological EEGs are expected to be present. You always know that beforehand. You can basically see there are cramps and they are always based on a “pathological change in the motoric cerebral cortex of the cerebrum”. Consequently, they are expected to be visualised in curve form. Therefore, the result is not new and surprising at all and at most rather a visual confirmation for what we already know anyway! Therefore, the taking of an EEG often turns into a scientific ‘hide and seek’ play because of the reluctance to admit not knowing much. However, there is still the desire to do something with modern technology which unfortunately is only diagnostic, not therapeutic! As a consequence, the more or less hopeful patient is kind of being misled because the result is always predetermined.

The only reasonable time to take a Control-Electroencephalogram is during a longer period without cramping in order to better judge the therapy and/or to investigate whether the patient has a particular potential for cramp remainders. However, even here misinterpretations are possible as the brain can never be scanned completely with electrodes attached to the skull because *as far as I know they only penetrate two centimetres deep. Brain electric activities that happen more in the centre of the brain therefore can't be captured.* We should always be aware of the fact these activities can neither be registered nor made visible graphically.

In any case, *the EEG should not be the central focal point of an anti-epileptic therapy* as it currently is in orthodox medicine. There, the focus is on manipulating the pathological curve of healing into what's considered normal, regardless of any losses. An Austrian female doctor with an interest in naturopathy perfectly summed up Hypsarrhythmia, a severe pathological EEG-curve at infantile BNS-cramps as following: “Orthodox medicine is only treating the EEG-picture and not the little patient.” You cannot say it any more appropriately.

=> **Epilepsy – A New Public Health Concern!!**

References

“Gentle Medicine – The True Causes of Disease, Healing, and Health”, Grätz, Joachim-F., 2021, Balboa Press, USA, www.gentle-medicine.com

“Klassische Homeopathie für die junge Familie”, 2 volumes (“Classical Homeopathy for the Young Family”), 3rd edition, Grätz, Joachim-F., Tisani Verlag, Oberhausen i. Obb., Germany

Short versions of this article in German were published in:

- 2008 in “ZeitenSchrift”, journal 60, Red Cross, Switzerland,
www.zeitenschrift.com/artikel/epilepsie-eine-neue-volkskrankheit#.VKdRUXtyFq
- 2014 in “raum&zeit”, journal 188, Ehlers Verlag, Wolfratshausen
www.raum-und-zeit.com/r-z-online/artikel-archiv/2014/ausgabe-188/epilepsie-durch-impfen.html

More information on *epilepsy, BNS-Cramps, West-Syndrome*, etc. at

www.tisani-verlag.de

➤ Klassische Homöopathie
(= Classical Homeopathy)

➤ Kasuistik
(= Causality)

Some *English pdf-files* available!

Dr.-Ing. Joachim-F. Grätz
Heilpraktiker, Klassische Homöopathie
Germany

Dr. Joachim-F. Grätz is an internationally recognized homeopath, very well known in German-speaking areas.

Origin of the article: An older, non-professionanl translation of an excerpt from the German version of the book “*Gentle Medicine – The True Causes of Disease, Healing, and Health*”, Grätz, Joachim-F., 2020, Balboa Press, USA, www.balboapress.com (website of classical homeopathy with many readable articles in German and some English versions additionally: www.tisani-verlag.de)

Dr. Joachim-F. Grätz has written further books such as “Sind Impfungen sinnvoll – Ein Ratgeber aus der homöopathischen Praxis” (9th edition), concerning vaccinations and homeopathy, and “Die homöopathischen Potenzen – Ein Ratgeber aus der Praxis” (2nd edition), concerning homeopathic potencies/remedies.

Questionnaires for homeopathic therapists as well as parents:

- *Questionnaire for Your Homeopathic Anti-Miasmatic Treatment:*
www.tisani-verlag.de/html/englishfragebogen.html
- *Questionnaire for the Homeopathic Treatment of Your Child:*
www.tisani-verlag.de/html/englishfragebogen1.html

Epilepsy – A New Public Health Concern?

TISANI VERLAG

See also Dr. Joachim-F. Grätz's two DVDs:

„Impffrei – Ein Grundstein für «chronische» Gesundheit“
 (“Vaccine-free – A cornerstone for «chronic» health”)

www.tisani-verlag.de/dvd



© www.tisani-verlag.de

Bücher für Ihre Gesundheit
www.TISANI-VERLAG.de

